

Adenocarcinoma arising in polyp – Risk estimation


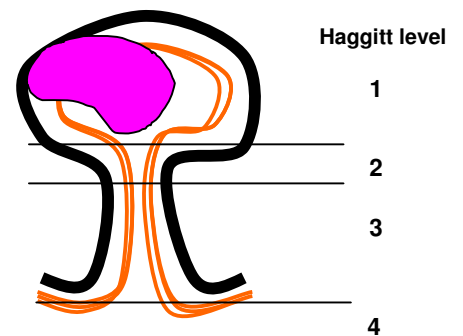
Favourable histology

- margin clear (>1mm))
- no poorly differentiated areas) < 0.5%
- Haggitt level 4 - upper SM only)
- - no adverse features < 1%

Unfavourable histology

- poorly differentiated ~ 30%
- margin involved ~ 50%
- margin close (<1mm clearance) ~ 25%
- lymphatic invasion^ ~ 40%
- Haggitt level 4 - deep SM > 15%

^ lymphatic invasion generally occurs in association with other poor prognostic features.



* Adenocarcinoma arising in a **sessile** lesion invades directly into the submucosa of the intestinal wall and may be regarded as **Haggitt Level 4** when it reaches submucosa.

References: Stein BL and Collier JA. Management of malignant colorectal polyps. *Surg Clin N Am* 1993; 73:47-66.

Nivatvongs S. Surgical management of early colorectal cancer. *World J Surg* 2000; 24:1052-55.